

Vitreous hemorrhage due to a retinal arteriovenous malformation – case report.

Authors:

Alexandr Stepanov^(1,4), Jan Studnicka^(1,4), Jaroslava Dusova^(1,4),
Nada Jiraskova^(1,4), Jan Lestak^(2, 3, 4*)

Institute:

1. Department of Ophthalmology, University Hospital and Charles Medical Faculty, Hradec Králové, Czech Republic
2. JL Clinic, V Hurkach 1296/10, Prague, Czech Republic
3. Faculty of Biomedical Engineering, Czech Technical University in Prague, Czech Republic
4. Faculty of Medicine in Hradec Kralove, Charles University, Czech Republic

*Corresponding author: Jan Lestak, MD, PhD, FEBO, MBA, LLA, DBA, FAOG
JL Clinic, V Hurkach 1296/10, 158 00 Prague 5, Czech Republic, E-mail:
lestak@seznam.cz

Acknowledgments

Author contributions: All co-authors have read the final manuscript within their respective areas of expertise and participated sufficiently in the study to take responsibility for it and accept its conclusions.

This study was supported in part by research project P37/07 (PRVOUK) from the ministry of the health, Prague, Czech Republic.

Conflict of interest statement: The authors state that there are no conflicts of interest regarding the publication of this article.

Abstract.

Arteriovenous malformations (AVMs) are vascular anomalies due to a failure in embryogenesis. They involve direct communication between an artery and a vein with no intervening capillary bed. We report a case of unilateral AVM with complication - vitreous hemorrhage.

Methods and Results.

This is a case report of small AVM which was complicated by vitreous hemorrhage. Lasercoagulation of the AVM was performed for the prevention of recurrent vitreous hemorrhage.

Conclusion.

Lasercoagulation of abnormal vessels can be performed in patients with a history of vitreous hemorrhage due to AVM with a good result.

Key words: Arteriovenous malformations; AVMs; vitreous hemorrhage; laser coagulation

Introduction

Retinal arteriovenous malformations (AVMs) are rare congenital developmental vascular anomalies and first described by Magnus in 1874 [6]. The most important clinical sign noted was marked arterial and venous dilatation associated with a tortuous pattern of vessels in a part of the retinal vascular system. The presentation ranges from small arteriovenous communications that are scarcely visible on retinal examination to pronounced dilatation of the entire retinal vascular system. Retinal AVMs are often detected during routine eye examination, and usually do not cause visual impairment. Men and women are affected equally. Single or multiple vascular anomalies may be present in the fundus. It is most common in the papillomacular area and the superotemporal retina [10].

Most cases of retinal AVMs follow a benign course, without evidence of clinical or anatomical progression. So, uncomplicated AVMs are not thought to cause vision loss. However, various associated ocular complications have been reported, including central retinal vein occlusion, cystic degeneration in the retina, macular edema, retinal ischemia, vitreous hemorrhage, retinal hemorrhage from possible hyperdynamic flow through small-caliber vessels, and a “steal” phenomenon caused by increased venous pressure with decreased arterial pressure [2, 7, 9-14].

The most common location of AVMs is the brain and it is here that they have been most considerably studied. Theory of the etiology and pathogenesis of AVMs supposes that these lesions are due to an increase in the number of vessels caused by a defect in vascular development, particularly angiogenesis [5]. It has been suggested that this is the cause of the dynamic vascular disturbance present in AVMs, resulting in an early alteration of angiogenesis, in contrast to what occurs in venous malformations; this is supported by the increase in the serum level of metalloproteinases detected in cases of AVM. The STAT proteins (signal transducers and

activators of transcription) are also involved in the pathophysiology of angiogenesis in AVMs. A group of these proteins is most active in the fetal period and may play a significant role in angiogenesis.

Arteriovenous malformations typically occur in the midbrain, and neurologic manifestations (e.g., cerebral or subarachnoid hemorrhage) depend on the size and location of the malformations. Patients may present with signs of a midbrain lesion, hemiparesis or hemiplegia, cerebellar dysfunction, or hydrocephalus; intellectual disturbances have also been reported [4, 8].

Case report

A 24-year-old Caucasian girl reported to the eye clinic with the complaint of painless decreased vision in her right eye. She had no history of infectious disease, trauma, systemic malignancy, or other systemic complaint. Best corrected visual acuity was 20/40 in the right eye and 20/20 in the left eye. Intraocular pressure was 18 mm Hg in both eyes measured by Goldmann applanation tonometry. Pupils were round and reactive in both eyes without evidence of relative afferent pupillary defect in either eye. Biomicroscopy of the anterior segment was unremarkable. Dilated fundus examination revealed normal findings in the left eye; in the right eye there was partial hemophthalmus, preretinal haemorrhage along the inferotemporal arcade and two vascular anomalies in the inferotemporal arcade and in the papillomacular bundle. Fundus fluorescein angiography (FAG) of the right eye showed rapid filling of vascular anomalies without leakage and with normal arteriovenous transit time (Fig. 1). No intervening capillary plexus was noted. FAG of the left eye was normal. Based on the history and objective status we established a diagnosis - vitreous hemorrhage due to a retinal arteriovenous malformation in the right eye, group 2. Magnetic resonance imaging of the brain was unremarkable for intracranial AVMs or bony lesions. Blood investigations including complete blood count with erythrocyte sedimentation rate, platelet count, serum lipids, prothrombin/activated partial thromboplastin time, autoimmune markers and serum homocysteine were all within normal limits.

In view of vitreous hemorrhage we decided to perform lasercoagulation of the vascular anomalies for the prevention of recurrent intravitreal hemorrhage and used the following parameters: spot size 200 μ m, duration: 200 ms, power: 300 mW, in sum 30 spots. Bleeding from the AVM started again during performance of the lasercoagulation (Fig. 2), but after additional pressure of the contact lens on the eye the bleeding was stopped. At the first evaluation 1 month after lasercoagulation, the hemophthalmus and preretinal haemorrhage had resolved remarkably, and visual acuity of the right eye had improved to a value of 20/20. Fundus fluorescein angiography showed a normal vascular network without anomalies (Fig. 3).

Discussion

A retinal AVM is a rare unilateral developmental vascular anomaly [15]. In 1973 Archer reviewed all published cases of congenital retinal AVMs. He divided the lesions into three groups (Table 1) [1]. Type 1 retinal AVM occurs when an arteriolar or abnormal capillary plexus is interposed between the major artery and vein. Type 2 retinal AVM is characterized by direct arteriovenous communication without intervening arteriolar or capillary segments. It is unusual to have an intracranial AVM associated with either a type 1 or 2 retinal AVM. Type 3 retinal AVMs appear as widespread retinal AVMs that exist morphologically as large-calibre convoluted vessels. These lesions of type 3 are frequently associated with AVM of the optic nerve, chiasm, and cerebral cortex. In this case the patient had type 2 retinal AVM.

The association of retinal AVM with facial and intracranial structures is known as Wyburn-Mason syndrome. Imaging methods include magnetic resonance imaging (MRI), computed tomography, digital subtraction angiography, computed tomography angiography, and magnetic resonance angiography (MRA). Cerebral angiography is typically reserved for symptomatic patients with type 3 AVMs given the associated risks [3]. Neurologic consultation may be warranted. Our patient had type 2 AVM which is not usually associated with intracranial vascular malformations on MRI.

Retinal AVMs most frequently occur in the superotemporal arcade (41%), papillomacular bundle (34%), and sometimes in nasal areas of the optic disk (6%) [10]. In this case the AVM presented in the papillomacular bundle region and in the inferotemporal arcade.

Classically, fluorescein angiography shows rapid filling of AVMs without leakage, as was the case with our patient.

Arteriovenous malformations are believed to be stable, unchanging lesions that pose little risk to vision. Occasionally, however, central retinal vein occlusion, vitreous hemorrhage, and retinal hemorrhage occur with these lesions [11, 13]. Mansour et al. proposed a hypothesis to explain potential complications: AVMs could lead to decreased arterial pressure and increased venous pressure, causing the surrounding retina to be ischemic due to hypoperfusion from a „steal“ phenomenon [13]. In addition, retinal or vitreous hemorrhage can occur in areas of capillary ischemia or areas of increased hydrostatic pressure. In this case the patient had vitreous hemorrhage.

Retinal AVMs usually are not treated because most are static. Laser therapy may be considered in patients with retinal edema and hard exudates in the fovea. In our case lasercoagulation of the AVM was performed for the prevention of recurrent vitreous hemorrhage.

Conclusions

Arteriovenous malformations present as dilated and tortuous retinal vessels of varying size and severity. Lasercoagulation of the abnormal vessels can be performed in patients with a history of vitreous hemorrhage due to AVM with good result.

Reference

1. Archer DB, Deutman A, Ernest JT, Krill AE. Arteriovenous communications of the retina. *Am J Ophthalmol* 1973;75(2):224–241
2. Brown DG, Hilal SK, Tenner MS. Wyburn-Mason syndrome. Report of two cases without retinal involvement. *Arch Neurol* 1973;28(1):67–69
3. Dayani PN, Sadun AA. A case report of Wyburn-Mason syndrome and review of the literature. *Neuroradiology* 2007;49:445-456
4. Ebert EM, Albert DM. The phakomatoses. In: Albert DM, Jakobiec FA, eds. *Principles and Practice of Ophthalmology*. 2nd ed. Philadelphia, Pa.: Saunders; 2000:5117–5146
5. El-Fiki M. Angiogenesis detection in cerebral arteriovenous malformations: Mediators and gene expression, and treatment hopes for the future. *World Neurosurg* 2012;78:422-424
6. Eleanore ME, Daniel MA. The phakomatoses. In: Albert DM, Jakobiec PA, editors. *Principles and practice of ophthalmology*. 2nd ed, vol 6. Philadelphia, Pa: WB Saunders Co; 1994.:5135-8
7. Hejsek L, Dusova J, Stepanov A, Rozsival P. Re-operation of idiopathic macular hole after failed initial surgery. *Biomed Pap Med Fac Univ Palacky Olomouc Czech Repub* 2014;158(4):596-599.
8. Hejsek L., Kana V., Rozsival P. et al. Total Avulsion of the Eye Globe Combined with an Injury of the Chiasm – a Case Report. *Czech and Slovak Neurology and Neurosurgery* 2014;77(4):510-514
9. Liu W, Sharma S. Abnormal retinal vessel. *Can Fam Physician* 2005;51:203-209
10. Mansour AM, Walsh JB, Henkind P. Arteriovenous anastomoses of the retina. *Ophthalmology* 1987;94(1):35–40
11. Mansour AM, Wells CG, Jampol LM, Kalina RE. Ocular complications of arteriovenous communications of the retina. *Arch Ophthalmol* 1989;107:232-236.
12. Qin XJ, Huang C, Lai K. Retinal vein occlusion in retinal racemose hemangioma: a case report and literature review of ocular complications in this rare retinal vascular disorder. *BMC Ophthalmol* 2014;14:101.
13. Schatz H, Chang LF, Ober RR, McDonald HR, Johnson RN. Central retinal vein occlusion associated with retinal arteriovenous malformation. *Ophthalmology* 1993;100(1):24–30

14. Telander DG, Choi SS, Zawadzki RJ, Berger N, Keltner JL, Werner JS. Microstructural abnormalities revealed by high resolution imaging systems in central macular arteriovenous malformation. *Ophthalmic Surg Lasers Imaging* 2010;9:1-4
15. Wyburn-Mason R. Arteriovenous aneurysm of mid-brain and retina, facial naevi and mental changes. *Brain* 1943;66(3):163–203

List of Annexures

Figure 1. Rapid filling of vascular anomalies without leakage.

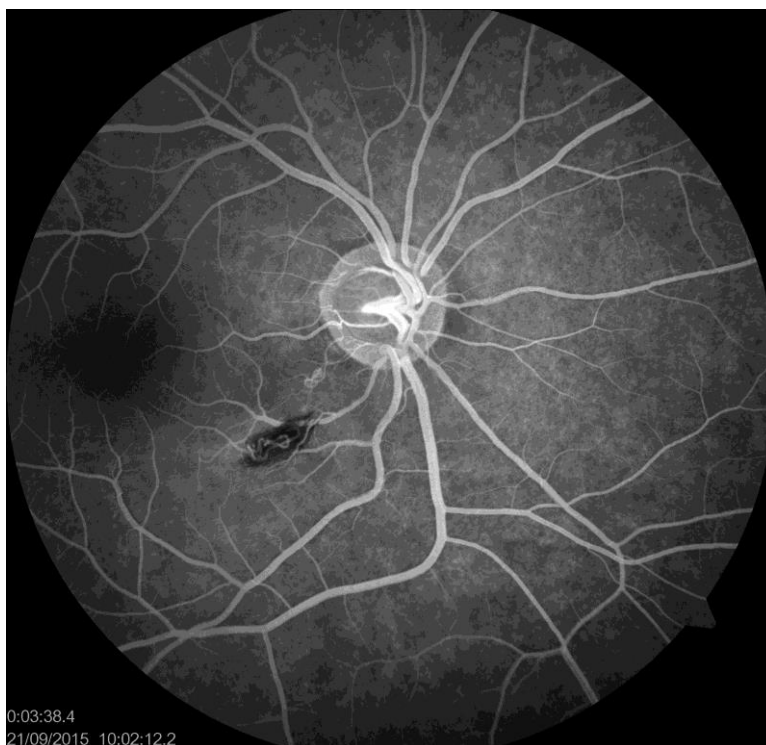


Figure 2. Fundus photography. Status after laser coagulation

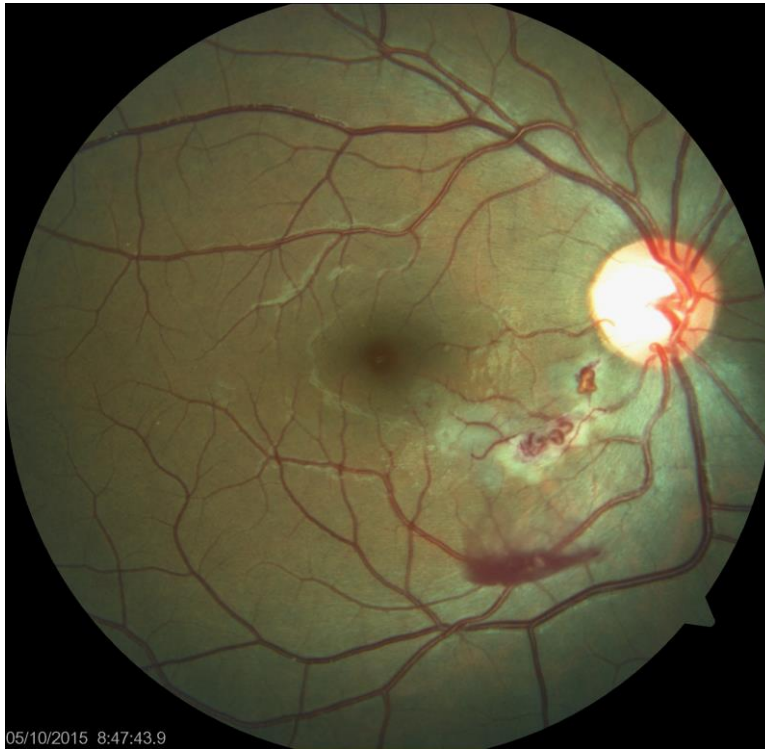


Figure 3. Normal vascular network without anomalies.

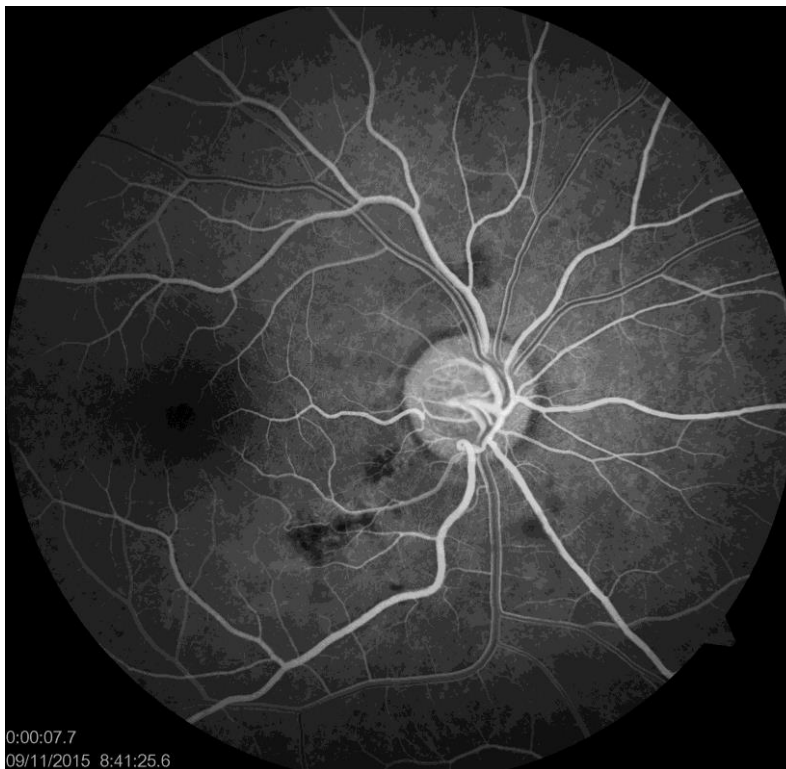

Table 1.*

Variants of Retinal Arteriovenous Malformation

Variant	Characteristics	Associations
I	Localized, well-compensated, intervening arteriolar or abnormal capillary plexus between the communicating vessels	Ocular or systemic malformations unusual
II	Direct arteriovenous malformation without intervening vascular components that may decompensate, leading to leakage of fluid (from slight leakage to extensive retinal edema, exudates, and hemorrhages)	Usually not associated with intracranial vascular malformations
III	Large and diffuse anastomosing channels, leading to difficulty in recognizing arterial and venous components; degenerative changes in the retina and poor vision	Intracranial involvement more likely than with other variants

* (Handa S, Chew RY, Au Eong KG. Convulsed vessels in the eye. Am Fam Physician 2008;78(8):981-983.)